

# CLINICAL CASES

Dent. Med. Probl. 2015, 52, 3, 371–376  
ISSN 1644-387X

© Copyright by Wrocław Medical University  
and Polish Dental Society

SAJID ALI<sup>A</sup>, ASMA ZOYA<sup>D</sup>, FEHMI MIAN<sup>A</sup>

## Forced Eruption in the Management of Subgingival Crown Fracture – an Interdisciplinary Approach: Case Reports

### Ekstruzja ortodontyczna w przypadkach poddziąsłowych złamań korzenia – leczenie interdyscyplinarne: opisy przypadków

Department of Conservative Dentistry & Endodontics, Dr. Z.A. Dental College, Aligarh Muslim University,  
Aligarh, Uttar Pradesh, India

A – research concept and design; B – collection and/or assembly of data; C – data analysis and interpretation;  
D – writing the article; E – critical revision of the article; F – final approval of article

#### Abstract

Traumatic fracture of the maxillary incisors and its sequelae impair the esthetics, function and phonetics. For a clinician, on the other hand, they pose a challenge for the establishment and accomplishment of an adequate treatment plan. A subgingival fracture line may involve biologic width resulting in restorative difficulties, where preservation of healthy attachment apparatus becomes paramount for a successful outcome. Among all the treatment options, such as periodontal crown lengthening, surgical extrusion, intentional replantation and extraction, orthodontic extrusion is the most conservative method. The aim is to obtain both a sound tooth margin which offers adequate crown ferrule and a sustained biologic width by bringing the periodontal apparatus along with it. The cases presented in this report describe an interdisciplinary approach involving orthodontic extrusion, conservative periodontal surgery, and cast post and core with porcelain-metal crown prostheses. This study concludes that a multidisciplinary treatment approach with cooperation among specialists to manage such a type of dental injury is essential for favorable esthetic and functional rehabilitation (*Dent. Med. Probl.* 2015, 52, 3, 371–376).

**Key words:** subgingival fracture, orthodontic extrusion, cast post and core.

**Słowa kluczowe:** złamanie poddziąsłowe, ekstruzja ortodontyczna, wkład koronowo-korzeniowy.

Dental trauma is very common in children and adolescents, involving the maxillary incisors predominantly. Various etiological factors of trauma are falls, road traffic injuries, acts of violence and sports accidents [1]. A complicated fracture as defined by the WHO system is “a fracture involving enamel and dentin with loss of tooth structure and exposure of the pulp”. Boys are more frequently involved than girls and occur in 0.9 to 13% of all dental injuries [2]. The impact of these injuries not only affects biological tissues, they have psychosocial influence as well [3].

Depending on the level of the fracture line and the amount of remaining tooth structure,

treatment may involve restorative, endodontic, orthodontic, surgical and prosthodontic procedures [4]. The treatment strategy for a subgingivally fractured tooth is challenging as providing functional along with esthetic rehabilitation is important for success [5]. Therefore technical knowledge and clinical experience are crucial to ascertain an accurate diagnosis and provide an appropriate treatment plan [6].

Several reports [1, 4, 7] describe various treatment modalities for complicated fractures: adhesive reattachment of the original fragment; fragment removal and restoration; gingivectomy and osteotomy (crown lengthening); orthodontic extrusion

with/without gingivoplasty; surgical extrusion; vital root submergence; and extraction followed by surgical implants or fixed partial dentures. Amongst all these, orthodontic extrusion is the most conservative procedure that does not involve loss of bone or periodontal support. In addition, surgical techniques involve resection of soft tissues and bone resulting in compromised bone support [8].

The main objective of orthodontic extrusion or forced eruption is to obtain both a sound tissue margin which offers adequate crown ferrule and a sustained biologic width by bringing the periodontal apparatus along with it [9]. This report presents two cases describing a multidisciplinary approach using orthodontic forced eruption to facilitate the prosthetic restoration of subgingivally fractured maxillary permanent central and lateral incisor.

## Case Report 1

A 24-year-old male patient came to the Department of Conservative Dentistry and Endodontics with the chief complaint of fractured upper front teeth. He did not have a significant medical history, and the results of the extraoral examination were unremarkable. He had reportedly had a motorcycle accident 12 days before. Clinical examination did not reveal any soft tissue injury but an oblique cervical fracture of tooth 11 and 12 with pulp exposure were present (Fig. 1a). These teeth were also tender on percussion. The fracture lines extended below the gingival level at the palatal surface of tooth 11 and at the distal surface of tooth 12. On radiographic examination, an oblique fracture was evident along with exposed pulp and periodontal ligament space widening (Fig. 1b).

With the diagnosis of oblique complicated crown root fracture, a definitive treatment plan was formulated comprising endodontic therapy of the involved teeth, followed by rapid orthodontic extrusion and a prosthetic rehabilitation of the teeth. The patient was informed about the cost,

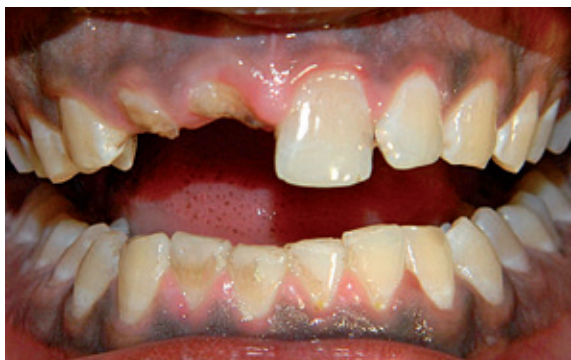

Fig. 1a. Preoperative photograph

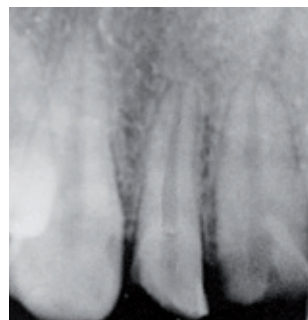


Fig. 1b. Preoperative radiograph

time commitments, and necessary plaque control procedures. Endodontic therapy was started in tooth 11 and 12. After administering local anesthetic, an access cavity was prepared. Pulp was extirpated and canals were thoroughly debrided with a copious irrigation of sodium hypochlorite (3.0%) and saline (0.9%). The working length was confirmed electronically as well as radiographically and established 1 mm short of apex. Biomechanical preparation was completed using the step back technique up to file #60. The canals were dried with paper points and calcium hydroxide (Ultracal® XS, Ultradent, South Jordan, Utah, USA) was given as intracanal medicament. After 1 week, the patient was asymptomatic, then the canals were obturated with the lateral condensation technique using the eugenol-based sealer Tubliseal EWT® (Sybron Endo Corporation, Orange, California, USA) (Fig. 1c). The patient was given temporary restoration and recalled after 2 weeks. When the patient was completely asymptomatic, the orthodontic appliance was given.

For extrusion, 022 x 028" MBT brackets (GAC International, Bohemia, New York, USA) were bonded, starting from tooth 14 to 24 (Fig. 1d). Active treatment was carried out for 6 weeks divided into 3 phases: the first 2 weeks with 0.014 inch round NiTi wire, the next 2 weeks with 0.016 inch

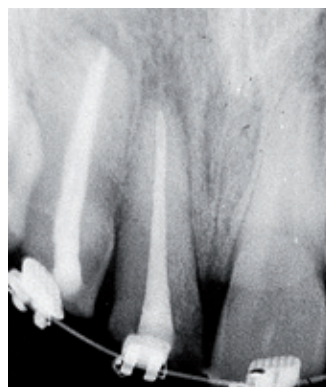
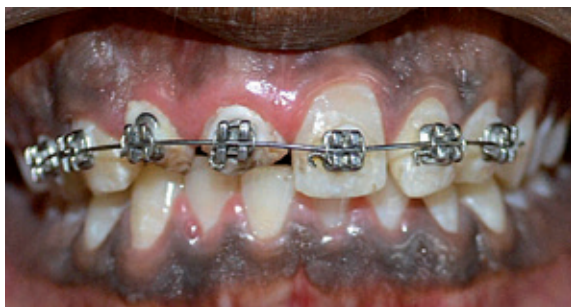
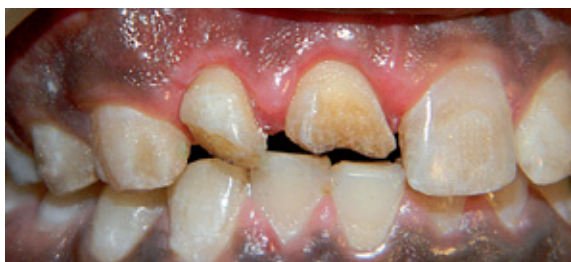Fig. 1c. Obturation radiograph



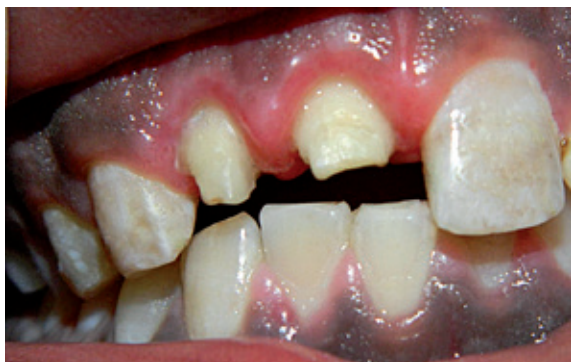**Fig. 1d.** Photograph of fixed orthodontic appliance

NiTi, and the final 2 weeks with 0.018 inch Ni-Ti wire. An extrusion force of about 50–60 g was applied. This modality was used for extrusion as well as alignment of teeth. An extrusion of approximately 3 mm was obtained within 6 weeks (Fig. 1e). The extruded teeth were retained with the 0.018 inch stainless steel arch wire for 3 weeks to prevent any relapse. At the end of the orthodontic extrusion procedure, there was some discrepancy between the gingival margin level of the treated tooth and the adjacent teeth. Thus, to correct this incongruity, a corrective periodontal surgical procedure along with gingival recontouring was performed (Fig. 1e).

Following the orthodontic extrusion, a core ferrule of 2 mm on the extruded part was prepared (Fig. 1f). Post spaces were created using peeso reamer #4, leaving apical 5 mm of gutta-percha to



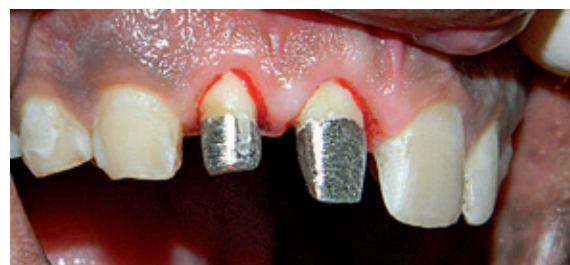**Fig. 1e.** Photograph showing completed extrusion with gingival recontouring



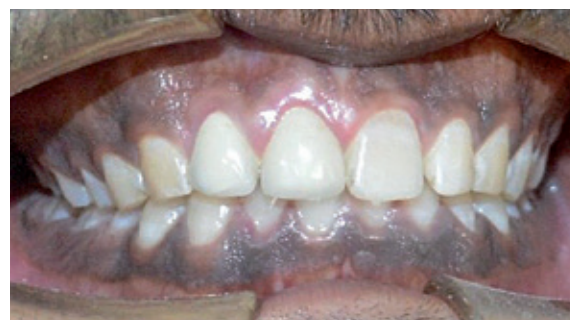**Fig. 1f.** Tooth preparation for cast post with adequate ferrule

maintain a good seal. Impression of the post spaces was taken with green inlay wax and the core part was carved. After casting of these impressions, metal posts were obtained and fitted in the teeth with dual cure resin cement (Paracore®, Coltene/Whaledent, Altstätten, Switzerland) (Fig. 1g). Preparation over these cores was done, 2 mm of crown ferrule were prepared in order to enhance fracture resistance of the remaining tooth structure and retention of the prosthesis. Finally, the teeth were restored with porcelain fused to metal crowns (Fig. 1h and 1i).

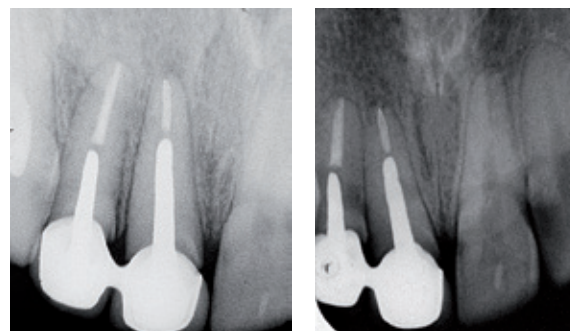
After 24 months, clinical and radiographic examination exhibited good esthetic results and periodontal health. No relapse occurred during the follow-up interval, and the tooth showed no signs of root resorption (Fig. 1j).



**Fig. 1g.** Seated cast post and core with tooth preparation for crown fabrication



**Fig. 1h.** Esthetic correction with porcelain fused to metal crowns



**Fig. 1i.** Radiograph of fractured teeth with completed restoration

**Fig. 1j.** Radiograph after 24 month follow-up restoration



## Case Report 2

A 20-year-old male patient reported to our department, with the chief complaint of fractured front teeth, pain and tenderness in the right upper region since one month after trauma due to a fall.

His medical history was noncontributory. Clinical and radiographic examination revealed fractured teeth 11, 12, 21 and 41. Teeth 21 and 41 had Ellis's class II fracture, while teeth 11 and 12 had class III fracture. Tooth 12 had a complex fracture such that the lingual half was separated from the small labial half, and the fracture line was extending subgingivally (Fig. 2a). Teeth 11 and 12 were tender on percussion and had exposed pulps. The palatal fragment of tooth 12 was mobile. Slight periodontal widening could be seen in the teeth 11 and 12 (Fig. 2b). The patient was informed of the treatment options and consent was taken to formulate the treatment plan.

The mobile palatal fragment was extracted and then RCT was performed in teeth 11 and 12 (Fig. 2c). As the remaining tooth structure for tooth 12 was too little for proper bracket placement, about 1–2 mm of gingivectomy was done (Fig. 2d). Teeth 21 and 41 required restoration which was given in the form of composite restorations. Orthodontic extrusion of tooth 12 was followed as given for the case above (Fig. 2e and 2f).

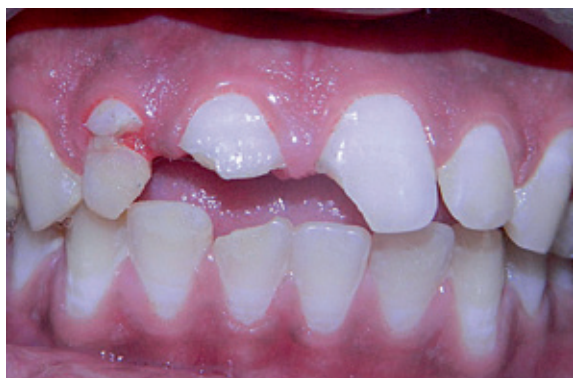

Fig. 2a. Preoperative photograph

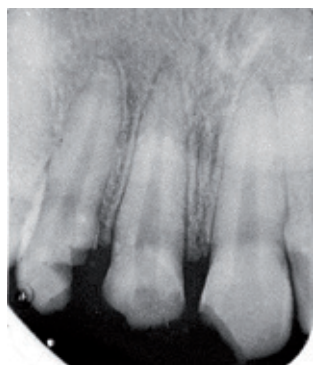


Fig. 2b. Preoperative radiograph

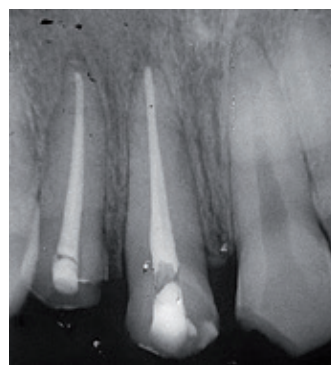

Fig. 2c. Obturation radiograph

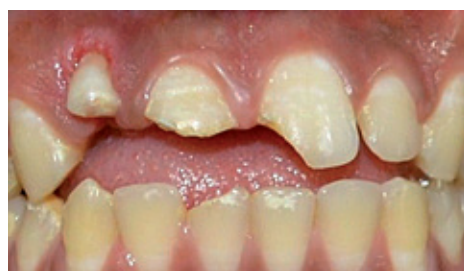

Fig. 2d. Gingivectomy of tooth 12 done to allow placement of a bracket

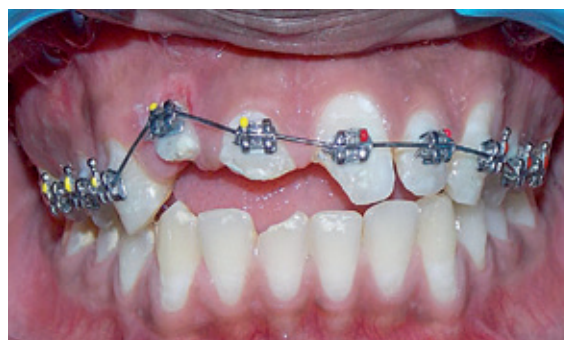


Fig. 2e. Photograph of fixed orthodontic appliance

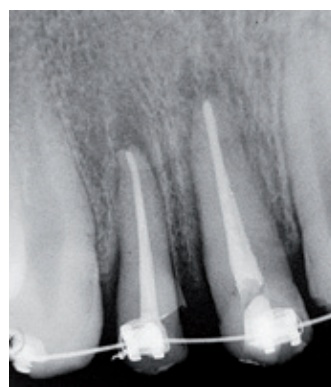
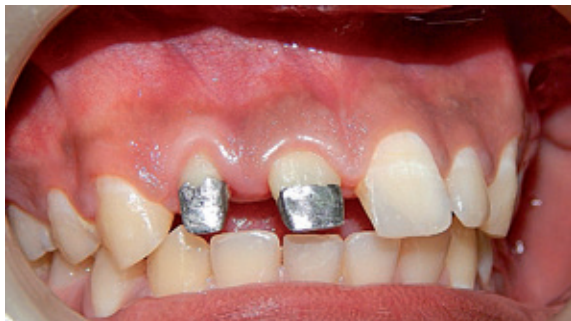

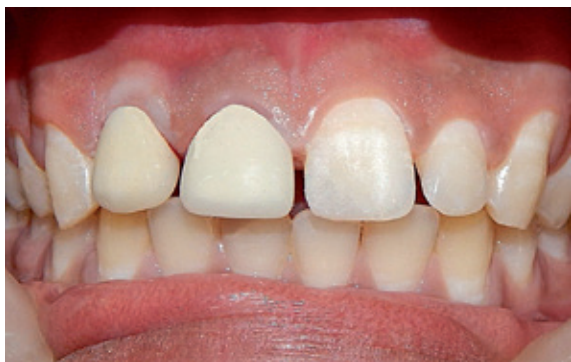Fig. 2f. Radiograph after 3 weeks of orthodontic extrusion

A 3–4 mm of extrusion was obtained and thus all the margins of fracture lines were brought out of the periodontium to obtain sound tooth mar-

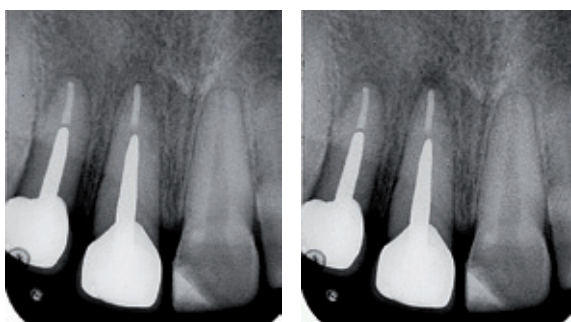
gins for restorations without violating the biologic width. Then teeth 11 and 12 were restored using cast post and core (Fig. 2g) and porcelain fused to metal crowns (Fig. 2h and 2i). After 18 month follow-up, clinical and radiographic results were satisfactory (Fig. 2j).



**Fig. 2g.** Seated cast post and core with tooth preparation for crown fabrication



**Fig. 2h.** Esthetic rehabilitation with porcelain fused to metal crowns



**Fig. 2i.** Radiograph of fractured teeth with completed restoration

**Fig. 2j.** 12 month follow up radiograph

## Discussion

Functional and esthetic rehabilitation of subgingivally fractured anterior teeth poses a restorative challenge to the clinician because of the encroachment of biologic width and consequent failure to achieve moisture and bleeding control [4].

This type of treatment should employ a multidisciplinary approach [5]. This case report presents successful multidisciplinary treatment of a subgingivally fractured tooth requiring the collaboration of endodontists, orthodontists, and periodontists.

Periodontal surgery (gingivectomy and osteotomy), orthodontic extrusion and surgical extrusion are the approaches for clinical crown lengthening. Orthodontic extrusion was used in this case as it offers several advantages, such as the fact that it is the most conservative, maintains optimum crown root ratio, does not violate biological width, and offers good esthetics [10–12].

Even though, upon extrusion, there is always some movement of the gingival and bony tissues, there is significantly more when extrusion is finished with lesser forces at a slower rate [13]. Because of that, rapid extrusion with heavy force was applied in this case and conservative periodontal surgery (gingivectomy, gingivoplasty), along with gingival recontouring was done to achieve the optimal esthetics and symmetry with the contralaterals. Several authors have stated that around 30–60 g of force is required for forced eruption, followed by 8–12 weeks [14] of stabilization period. Accordingly, about 50 g of force was employed; however the retention period was reduced to 2 weeks when the radiographic appearance suggested adequate periapical healing. Moreover, final restoration itself aids in the prevention of relapse [15].

Extrusion was done to obtain 4 mm of supra-gingival tooth structure so that an adequate ferrule effect could be obtained. A ferrule effect is achieved by metal collar of the crown surrounding the parallel walls of the dentine, extending coronal to the shoulder of the preparation. This helps in enhancing the resistance and retention form for both the tooth and restoration [16]. The type of post selected depends on the amount and quality of remaining tooth structure. Rigid metal posts are indicated for teeth with minimal tooth structure. Cast metal post and core becomes a single unit and limits movements of the core by itself, thus avoiding disruption of the crown margin and cement seal. In structurally-compromised teeth which lack cervical stiffness, fiber posts are contraindicated because they cause excessive flexion. When less than 2–3 mm of cervical tooth structure remains and limited ferrule effect can be obtained, rigid cast metal posts resist distortion [17]. Hence, cast metal posts were given in the present cases.

This case report describes the importance of a combined endodontic, orthodontic, and periodontic approach to achieve a desirable outcome of traumatized maxillary anterior teeth. For the es-

thetic and functional rehabilitation of such cases, a definite treatment protocol should be followed. Among all the treatment options, orthodontic extrusion is the most conservative and more natural to the patient but also requires time, commitment,

and motivation from the patient and the dentist. The keys to long-term success in this case are: efficient evaluation, a proper treatment plan, and patient cooperation during the entire course of treatment as well as regular recall visits.

## References

- [1] ANDREASEN J.O., ANDREASEN F.M., TSUKIBOSHI M.: Crown-root fractures. [In:] Textbook and Color Atlas of Traumatic Injuries to the Teeth. Eds.: Andreasen J.O., Andreasen F.M., Andersson L., Blackwell Munksgaard, Copenhagen 2007, 1<sup>st</sup> ed., 314–336.
- [2] TAPIAS M.A., JIMENEZ-GARCIA R., LAMAS F., GIL A.A.: Prevalence of traumatic crown fractures to permanent incisors in a childhood population: Mostoles, Spain. *Dent. Traumatol.* 2003, 19, 119–122.
- [3] CORTES M.I., MARCENES W., SHEIHAM A.: Impact of traumatic injuries to the permanent teeth on the oral health-related quality of life in 12–14-year-old children. *Community Dent. Oral Epidemiol.* 2002, 30, 193–198.
- [4] OLSBURGH S., JACOBY T., KREJCI I.: Crown fracture in the permanent dentition: Pulpal and restorative considerations. *Dent. Traumatol.* 2002, 18, 103–115.
- [5] POI W.R., CARDOSO LDE C., DE CASTRO J.C., CINTRA L.T., GULINELLI J.L., DE LAZARI J.A.: Multidisciplinary treatment approach for crown fracture and crown-root fractured – a case report. *Dent. Traumatol.* 2007, 23, 51–55.
- [6] DE CASTRO M.A., POI W.R., DE CASTRO J.C., PANZARINI S.R., SONODA C.K.: Crown and crown-root fractures: an evaluation of the treatment plans for management proposed by 154 specialists in restorative dentistry. *Dent. Traumatol.* 2010, 26, 236–242.
- [7] VILLAT C., MACHTOU P., NAULIN-IFI C.: Multidisciplinary approach to the immediate esthetic repair and long-term treatment of an oblique crown-root fracture. *Dent. Traumatol.* 2004, 20, 56–60.
- [8] BACH N., BAYLARD J.F., VOYER R.: Orthodontic extrusion: periodontal considerations and applications. *J. Can. Dent. Assoc.* 2004, 70, 775–780.
- [9] MINSK L.: Orthodontic tooth extrusion as an adjunct to periodontal therapy. *Compend. Contin. Educ. Dent.* 2000, 21, 768–774.
- [10] BACH N., BAYLARD J.F., VOYER R.: Orthodontic extrusion: periodontal considerations and applications. *J. Can. Dent. Assoc.* 2004, 70, 775–780.
- [11] BENENATI F.W., SIMON J.H.S.: Orthodontic root extrusion: its rationale and uses. *Gent. Dent.* 1986, 34, 285–289.
- [12] HEITHERSAY G.S.: Combined endodontic-orthodontic treatment of transverse root fractures in the region of the alveolar crest. *Oral Surg. Oral Med. Oral Pathol.* 1973, 36, 404–415.
- [13] BROWN G.J., WELBURY R.R.: Root extrusion, a practical solution in complicated crown-root incisor fractures. *Br. Dent. J.* 2000, 189, 477–478.
- [14] PROFFIT W.R., FIELDS H.W., SARVER D.M.: Contemporary orthodontics. Mosby, St. Louis 2007, 4<sup>th</sup> ed., 312–313.
- [15] MALMGREN O., MALMGREN B., FRYKHOLM A.: Rapid orthodontic extrusion of crown root and cervical root fractured teeth. *Endod. Dent. Traumatol.* 1991, 7, 49–54.
- [16] SORENSEN J.A., ENGELMAN M.J.: Ferrule design and fracture resistance of endodontically treated teeth. *J. Prosthet. Dent.* 1990, 63, 529–536.
- [17] MARCHI G.M., MITSUI F.H., CAVALCANTI A.N.: Effect of remaining dentine structure and thermal-mechanical aging on the fracture resistance of bovine roots with different post and core systems. *Int. Endod. J.* 2008, 41, 969–976.

## Address for correspondence:

Sajid Ali  
 Department of Conservative Dentistry & Endodontics  
 Dr. Z.A. Dental College  
 Aligarh Muslim University  
 Aligarh  
 Uttar Pradesh  
 India  
 E-mail: sajid.bds.amu@gmail.com

Conflict of interest: None declared

Received: 24.02.2015

Revised: 10.03.2015

Accepted: 16.03.2015